

Military Technical College
Kobry Elkobbah,
Calro, Egypt



2nd International Conference
on Electrical Engineering
ICEENG 99

CORRECTION EFFECTS OF MACHINE DEPENDENCY ON THE TEXTURAL PARAMETERS OF ULTRASOUND IMAGES

Ahmed M. Badawi^{**} Ph.D., S.E. Shouman^{***} Ph.D., Yasser M. Salman. B.Sc.

ABSTRACT

In this paper we presented the effect of correction of machine dependency such as LookUpTable (LUT) correction, Time-Gain-Control(TGC) correction, Diffraction and Focusing correction on the textural parameters of ultrasound images. The group of texture parameters are: histogram parameters, coocurrence matrix parameters, first order gradient parameters, grey level run length matrix parameters, texture feature Descriptors (TFD parameters), acoustical parameters. Mapping this parameters into color coded display improve the visual inspection to the sonographers.

After correction an increase of some textural parameters and decrease of others improve the visual inspection from the ultrasonographers point of view. These results can improve the segmentation quality of the ultrasound images that will facilitate the build of 3D ultrasound images and can have an accurate measurement from the images and from the 3D data.

KEY WORDS

LookUpTable (LUT), Time-Gain-Control(TGC), Diffraction and Focusing, textural parameters.

*Graduate student, Dpt. of Electronic Eng., M.T.C, Kobry Elkobbah, Egypt.
** Ph.D., Dpt. Of Biomedical Eng., Faculty of Engineering, Guiza, Egypt.
***Associate professor, Dpt. of Electronic Eng., M.T.C, Kobry Elkobbah, Egypt.

1. INTRODUCTION

Pulsed-echo ultrasound is a non-invasive technique capable of visualizing an internal structure of soft tissues and as such it is considered to be an extremely important and valuable tool of medical diagnosis. However, despite their importance, existing ultrasonic systems have a number of important shortcomings. The main problem stems from the fact that presently the diagnosis is, usually, of qualitative nature. The physician has relied on detection of inhomogeneities between echo amplitudes received from the neighboring areas of the image. Such an approach is, of course, subjective and consequently problematic in itself. Moreover, in certain cases the disease attacks the entire tissue area, say, entire liver (diffuse liver diseases). Then, the ultrasonic image will be homogeneous, and as a result the diagnosis is sometimes difficult [1].

Tissue characterization is a term that usually refers to the quantitative estimation of tissue or image features leading to a more accurate distinction of normal and abnormal tissues; the results of tissue characterization are quantitatively interpreted using numerical values. It aims to provide additional information about tissues not available by viewing ordinary images of the ultrasound B-scan. Thus; gained information are quantitative and is far less operator dependent than the usual B-scan images. The quantitative analysis of using ultrasound signals as an aid to the diagnosis of diffuse disease has been described by many researchers [2].

When analyzing echographic images, the processed data depends strongly on the setting of the equipment. So, the overall gain, Time-Gain-Compensation(TGC), Diffraction and Focusing, pre-and post processing of the grey levels, all play a role in the estimation of the texture parameters. To correct the effects of these dependencies, we used images from tissue mimicking phantom with the same setting of the echographic equipment as during the clinical procedure. The acoustic properties of the phantom were estimated in the device developed for acoustic microscopy. In this paper we used these images after correction (LookUpTable(LUT) correction, Time Gain Control correction, Diffraction and Focusing correction) and applied our program to the images before and after correction. In each case our program extracts the parameters, maps these parameters into color coded images then analyzes the difference occurred in image parameters after correction[3].

2. DATA ACQUISITION

Data acquisition systems

The data acquisition system and aTL machine system were developed at *Dr. Abou-Bakr's Youssef Clinic and Kasr Elaini medical school Hospital, Cairo, Egypt.*



Fig.1. The aTL Ultramark 9 machine, the acquisition system, and the computer

In the system shown in fig.1., the video output of an aTL Ultramark model 9 ultrasound machine was connected to a Nova-Microsonics workstation for image acquisition. The cineloop images are captured at a rate of 30 frames/sec for fully inspired controlled limb movement and controlled inspiration patients. The images are captured with grey level resolution of 8 bits/pixel at 3.5 MHz .

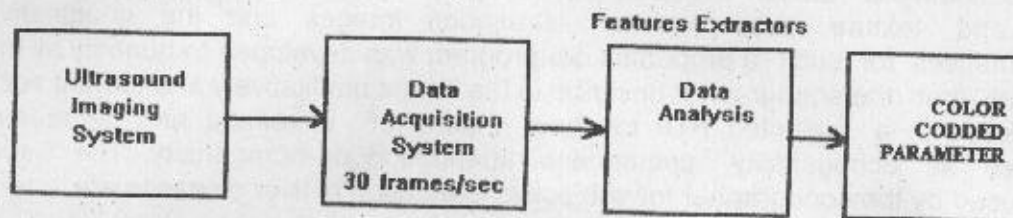


Fig. 2 : A block diagram for different phases, data acquisition, analysis and mapping.

The Images are then reformatted from the DEF format of the Nova-Microsonics workstation and analyzed at a P-II-300 computer machine. The axial resolution at this setting was 32 pixel/cm and lateral resolution 26 pixels/cm for the first system settings.

A software was developed on this system to allow the sonographer to define the region of interest in the image for tissue characterization and for further motion and elasticity analysis (WINDOWS95 operating systems).

Systems settings

To obtain a reproducible results, the following parameters were standardized for all tissue characterization procedures [4-6] for the system

- *Ultrasound machine settings for the original images:* e.g., TGC, FOCUS, and ZOOM controls, which can change the overall image gain and produce zooming effects and hence they can deviate the image statistics in an unpredictable way. Moreover, the frequency of ultrasound waves used must be the same for all the patients since the attenuation of ultrasonic waves depends mainly on this frequency. The diffraction and focussing for system were corrected using two different tissue mimicking AIUM phantoms at 0.5 dB/cm.MHz and the other at 0.7 dB/cm.MHz.
- *Images after correction:* The LUT correction, TGC correction, diffraction and Focusing correction must be done before applying our algorithms.
- *Region-of-interest (ROI) size and shape:* to obtain a reliable statistics, the number of pixels in the region of interest must be at least a thousand pixels (1cm * 1cm, 30*30 pixels). A practical ROI size must be taken to cover texture regions in the image and far from edges. Also, the square shape of the region should be maintained during all procedures, and for mapping the polygon region should be maintained to be more flexible to select the ROI.
- *Fasting condition of the patient:* fasting for 8 hours before the scan to avoid the effect of changing liver glycogen and water storage of ultrasound attenuation.

Data acquisition for the system was obtained in a transverse subcostal section taken for patients just preceding a needle biopsy procedures on their livers. The data from the pathology laboratory were used with the other biochemical, clinical, and other measurements to identify the exact condition of all obtained images.

3. MATERIALS AND METHODS

Towards finding a relation between the sonographers subjective evaluation for the tissue and texture properties of ultrasound images and the quantitative representatives for such a properties our program was developed to quantify all the properties that the sonographer describe in the image qualitatively and to map such a properties in a selected ROI to show regions of increased and decreased properties as echogenicity, coarseness, attenuation or homogeneity. The visual criteria used by the sonographer for subjective evaluation of liver diseases are :

- parenchymal echogenicity and penetration
- peripheral vascular pattern and portal vein fibrosis .
- Liver and caudate lobe size, ascites, and spleen size.
- Site, contour, size, and echo pattern of malignant lesions if found.

Due to the low diagnostic accuracy of the subjective evaluation the clinician are forced to do the golden "BIOPSY" test to know the histopathology of the liver .In our program we quantitatively described the echogenicity, the penetration, and homogeneity with numerical computerized analysis for the ultrasound image for different groups and categories of parameters. Some of these parameters are independent of the depth. Size and shape of ROI selected. Some of these parameters are dependent on the spatial distribution of the grey levels in the image and others are not. The categories of parameters are:

1. Histogram parameters:

These are mean grey levels (MGL, which characterize the echogenicity), grey level variance (VAR), signal to noise ratio (MGL/VAR), skewness (characterizes the deviation of the grey level distribution from a symmetrical reference distribution). Curtosis. (characterizes the steepness of the grey level distribution) and five of the relevant grey level histogram percentiles [7] .

2. Co-occurrence matrix parameters:

These are contrast (CON, characterizes the tissue coarseness), entropy (ENT, characterizes tissue homogeneity), correlation (COR, characterizes a measure of linearity in the relationship of the grey levels of the co-occurrence matrix). And angular second moment (ASM, characterizes grey level clustering transition in the co-occurrence matrix) [7] .

3. First order gradient parameters:

These are $Absv_{ave}^*$, $Absv_{var}^*$, $Absv_{var}$, Most Dominant, Edge Direction (MDE), Relative frequency of the most dominant edge (RFMDE), [7] .

4. Grey level runlength:

It characterizes the count distribution of the grey levels in histogram. These are Run percentage (RPER), Long-Run emphasis (LREM), Grey level distribution (GDIST) Runlength distribution (RLDIST) [7].

5. Texture feature descriptor (TFD) parameters:

These Coarseness (coarse), Homogeneity(hom), Mean Convergence (MC), Variance (Var) , Entorpy(Entorpy),Runlength Density(RLD), Regularity), Grey level Resolution Similarity (GLRS) [7].

6. Acoustical parameters:

These are attenuation coefficient (ATN, characterizes penetration) [8-12] and the backscattering coefficient (BSC, Characterizes backscattered power to the transducer).

Color coded parameters:

The mask 32X17 is being traversed along the pixels in the image to calculate the parameters of the central pixel.

Our program contains pull down menus like file (new,open,close,save, save as, print, print setup), edit (undo, cut, copy, paste) , view (toolbar, status bar), region style (polygon), setting (frequency , pixels per cm measurements either manually or automatically), Parameters (calculation, display,mapping), correction (LUT correction, TGC correction, Diffraction correction curve, diffraction & Focusing correction).

Parameters calculation:

We use our program to calculate the parameters after and before image correction, See figs(3-9) to detect the difference occurred after and before correction.

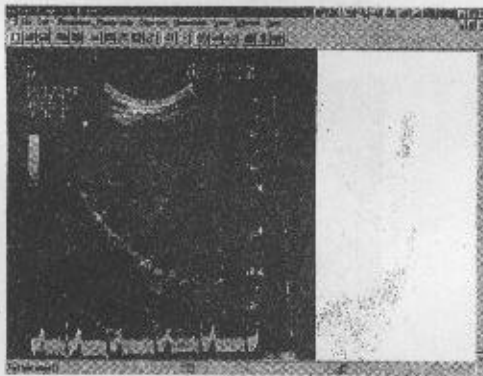


Fig 3.a Ultrasound image before correction and a selected ROI

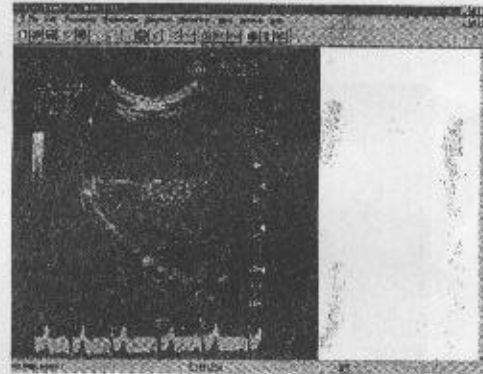

Fig 3.b Ultrasound image after correction and a selected ROI



Fig.4.a Textural parameters before correction




Fig.4.b Textural parameters After correction

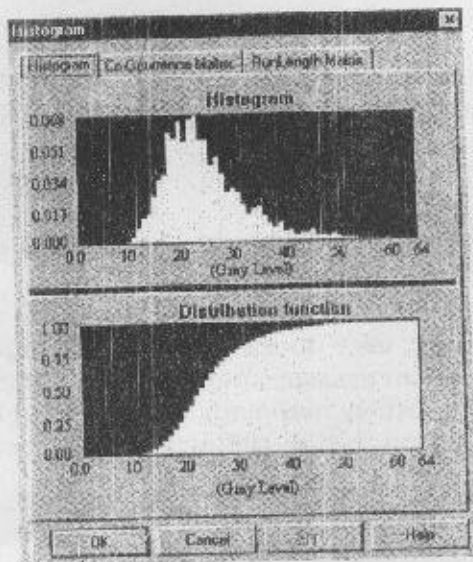


Fig. 5.a Histogram and distribution function before correction

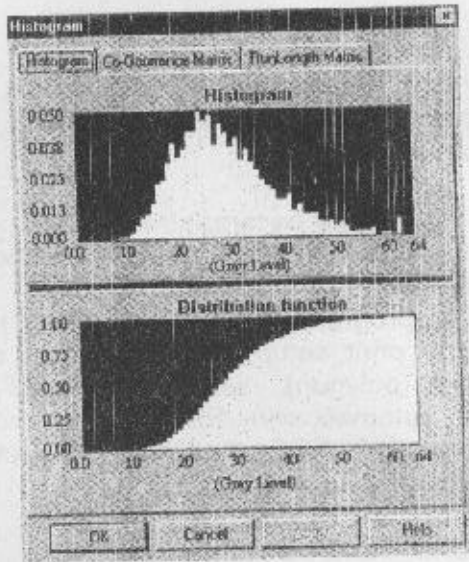


Fig. 5.b Histogram and distribution function after correction

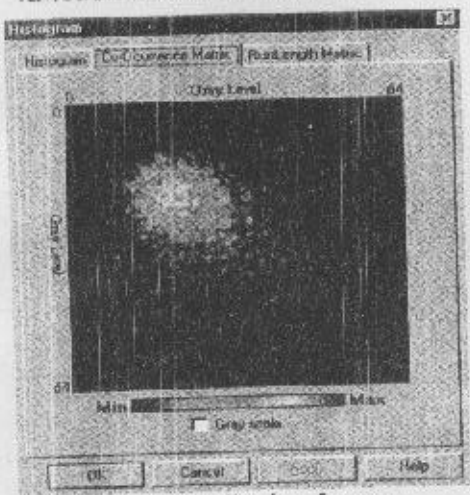


Fig. 6.a Color display for co-occurrence matrix before correction

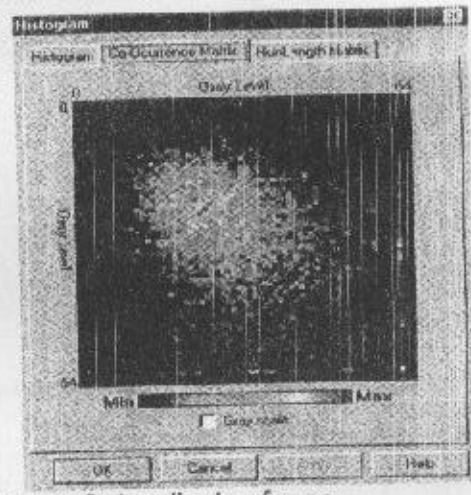


Fig. 6.b Color display for co-occurrence matrix after correction




Fig. 7.a Color display for runlength matrix before correction



Fig. 7.b Color display for runlength matrix after correction




Fig.8.a A grey scale and color display for the attenuation before correction




Fig.8.b A grey scale and color display for the attenuation after correction




Fig.9.a A display for TFD parameters and joint probability matrix before correction




Fig.9.b A display for TFD parameters and joint probability matrix after correction

Mapping parameters :

To map the parameters into color or grey scale codes select a polygon region from the image then select the set of parameters to be coded. The results of mapping the texture features before and after correction are shown in figs. (10-21) where the difference is shown for every image pixels. Here is an examples for mapping parameters in the ultrasound images where the color codes indicates the maximum and minimum regions in the images.

The next figures (10-21) show the mapping profile before and after correction and the color toolbar (at the left of the image) indicates the maximum (in red) and the minimum (in blue).

At fig. (10.a) MGL before correction the colors inside ROI indicates that the maximum values lays at left and down regions and the minimum values occurred at the image peripherals , fig. (10.b) shows MGL after correction , it clearly show how the MGL increase at the center of the image and at the left peripheral which means increasing in the brightness of the image after correction.

Fig. (11.a) illustrates variance before correction, fig. (11.b) shows decreasing in the variance at the left and central regions on the image and slightly increasing at down left region.

Fig. (12.a) illustrates PER90 before image correction, fig. (12.b) shows that the PER90 values increased at the central region, left peripheral on the image.

Fig. (13.a) shows PER10 before image correction, fig. (13.b) shows that PER10 after image correction, which explains increasing of the PER10 values at the central regions and left peripherals.

Fig. (14.a) illustrates the ABSV+ before correction, fig. (14.b) illustrates that the ABSV+ after image correction generally decreases for overall image pixels and slightly increasing at the central region.

Fig. (15.a) shows the ABSVAR+ before correction, fig. (15.b) shows that ABSVAR+ increased at the central region and no relevant change occurred at the other regions.

Fig. (16.a) shows BSC before correction, fig. (16.b) shows BSC after image correction which illustrates decreasing at the central region and left peripheral and slightly increasing at the right peripheral.

Fig. (17.a) illustrates the ATN before correction , fig. (17.b) shows that ATN values increase at the central region and at the upper left , right peripheral regions on the image.

Fig. (18.a) illustrates the COR before correction, fig. (18.b) illustrates the COR after correction and it seems to be no remarkable changes occurred in the image before and after correction.

Fig. (19.a) illustrates the ENT before correction, fig. (19.b) shows how ENT values highly increases at the overall image regions after correction which means increasing homogeneity of the image after correction.

Fig. (20.a) shows the CON before correction, fig. (20.b) shows that CON values increase at the central pixels on the image and decreased and the down region.

Fig. (21.a) shows the TFDMC before correction, fig. (21.b) illustrates slightly increasing at the central region , decreasing on the other regions.

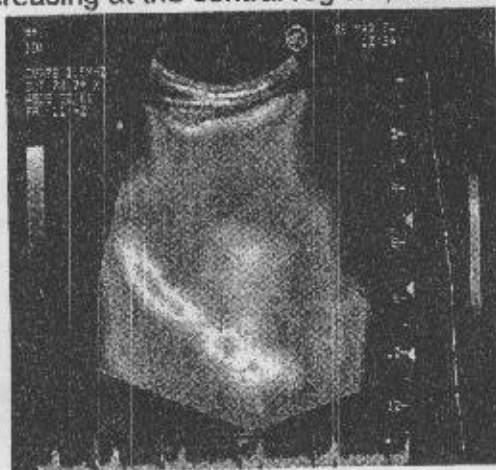


Fig.10.a MGL before correction

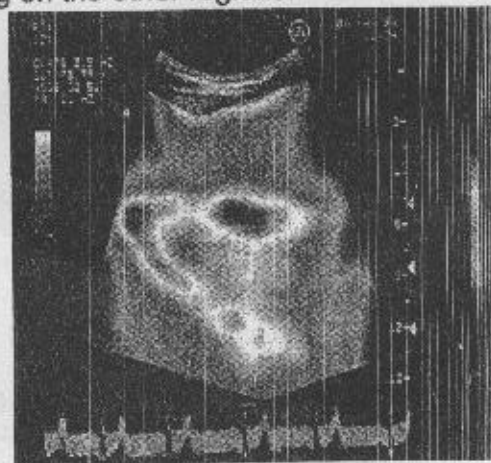

Fig.10.b MGL after correction

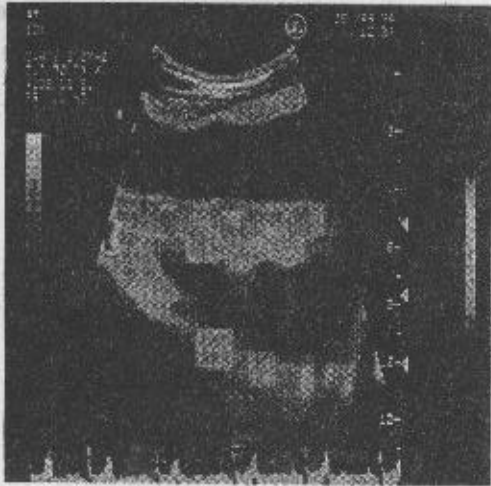


Fig. 11.a VAR before correction

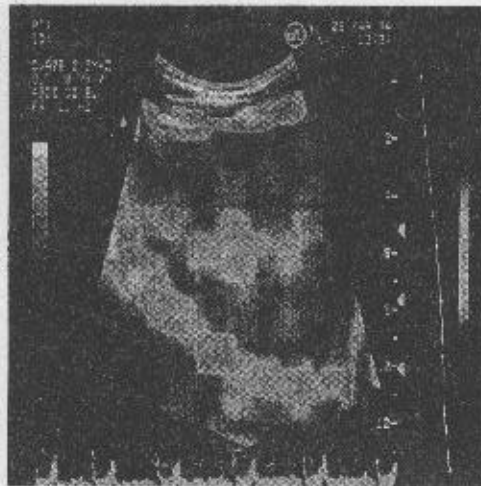

Fig. 11.b VAR after correction

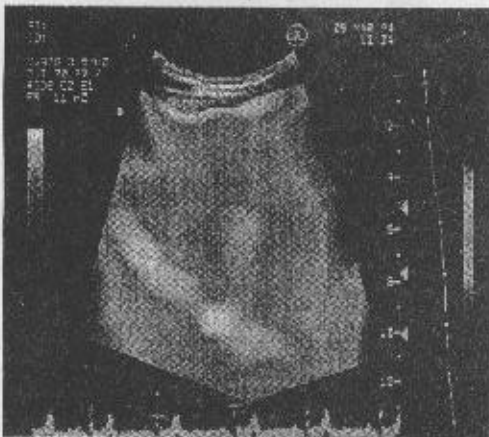


Fig. 12.a PER90 before correction

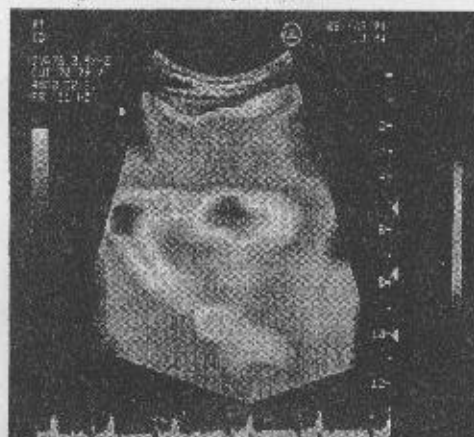

Fig. 12.b PER90 after correction

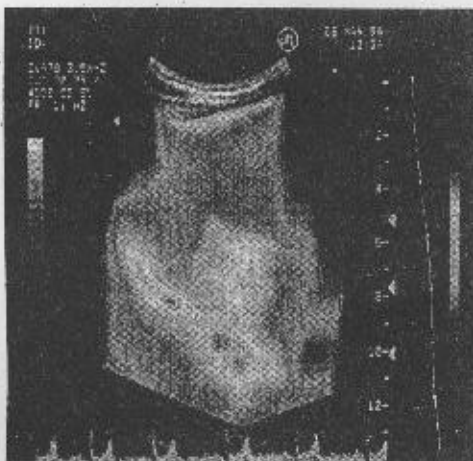


Fig. 13.a PER10 before correction

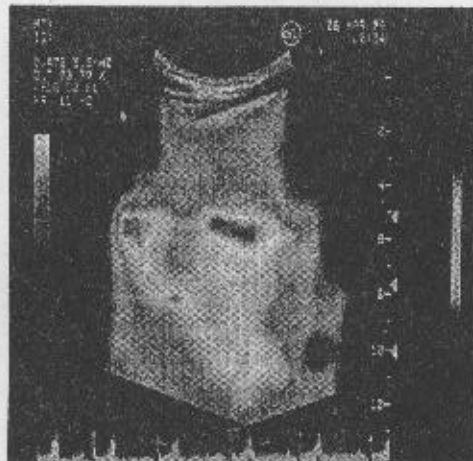


Fig. 13.b PER10 after correction

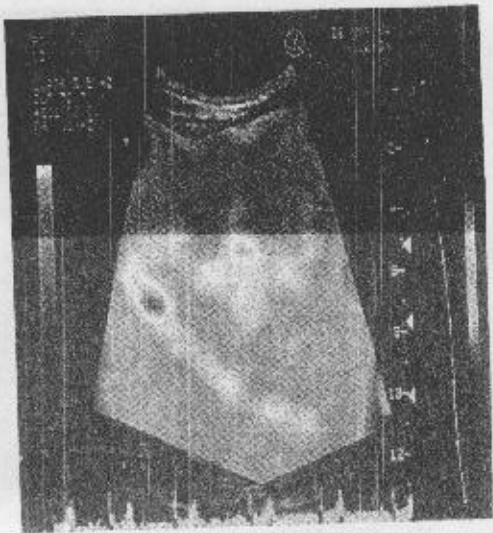


Fig. 14.a ABSV+ before correction

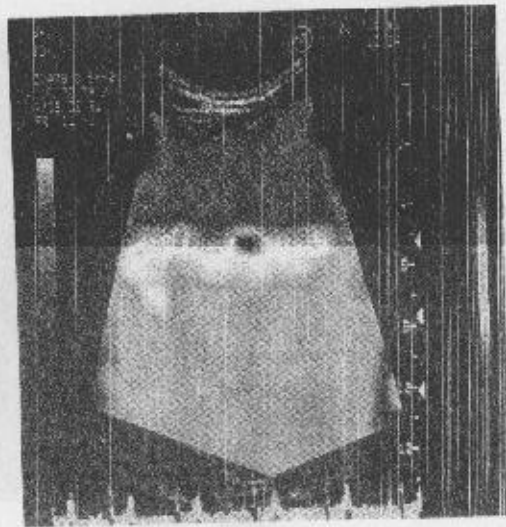


Fig. 14.b ABSV+ after correction

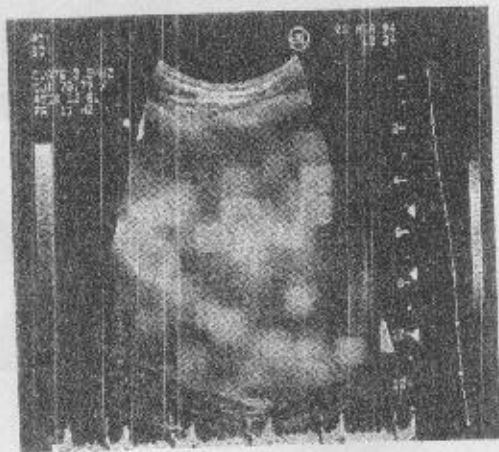


Fig. 15.a ABSVar+ before correction

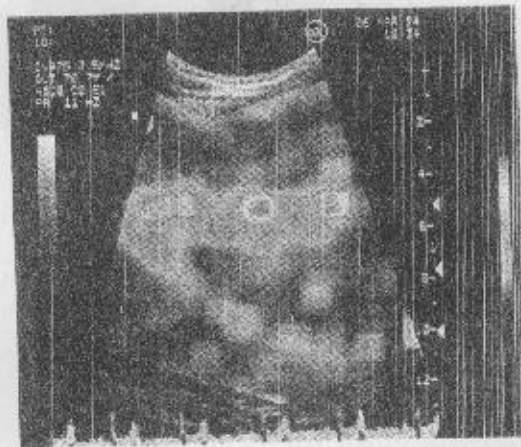


Fig. 15.b ABSVar+ after correction

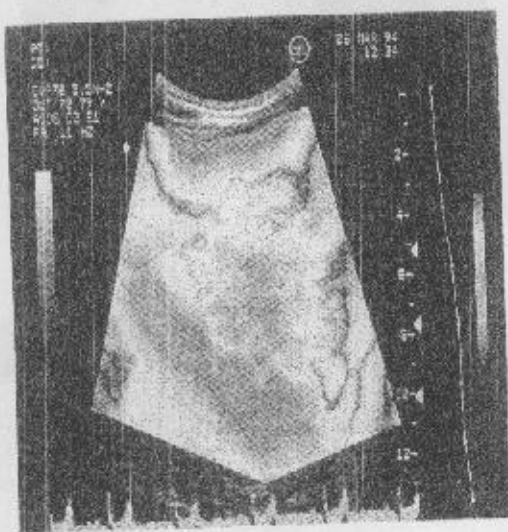


Fig. 16.a BSC before correction

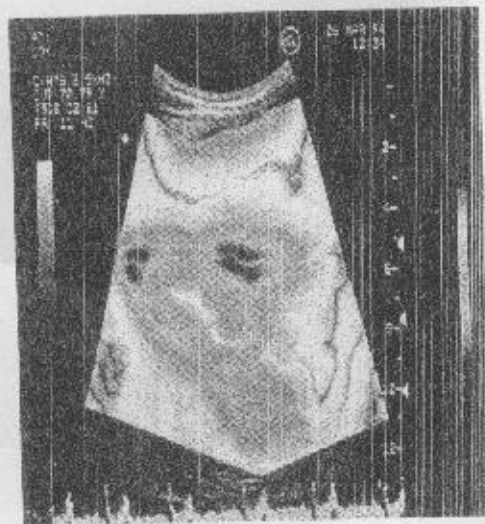


Fig. 16.b BSC after correction

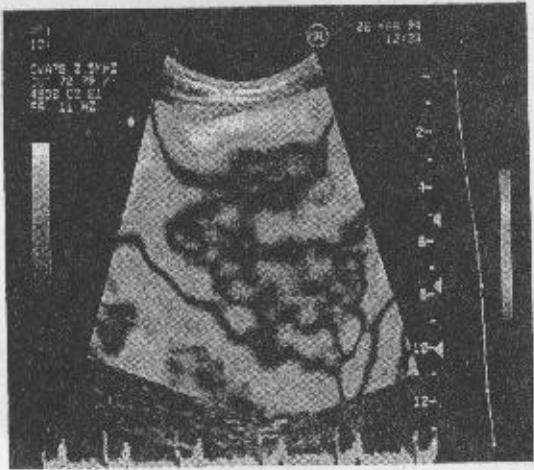


Fig.17.a ATN before correction

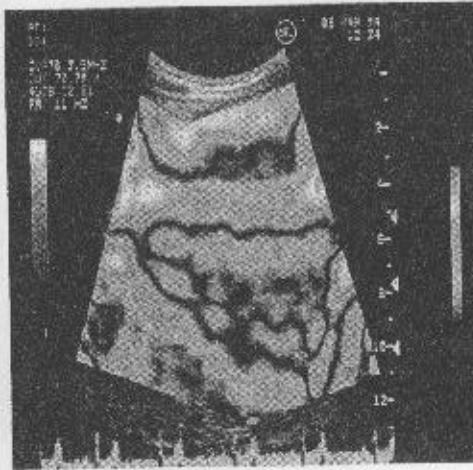


Fig.17.b ATN after correction

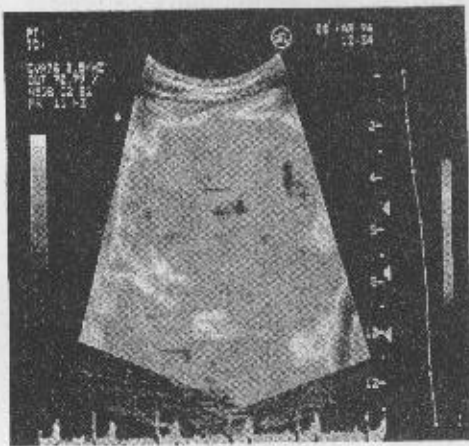


Fig.18.a COR before correction

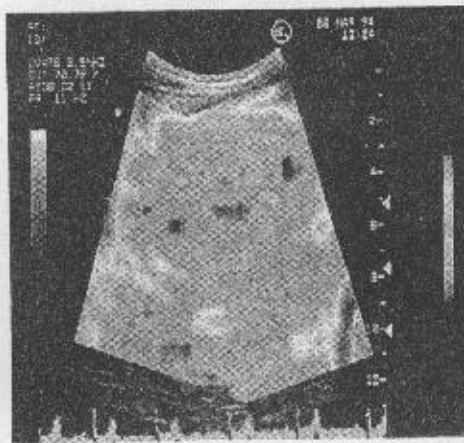


Fig.18.b COR after correction

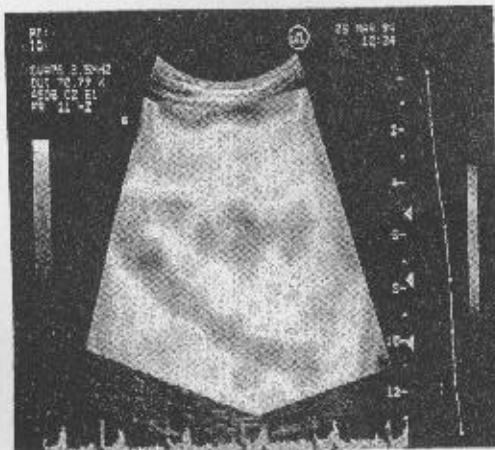


Fig.19.a ENT before correction

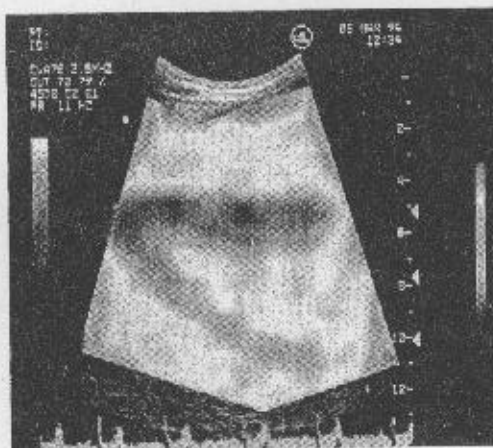


Fig.19.b ENT after correction

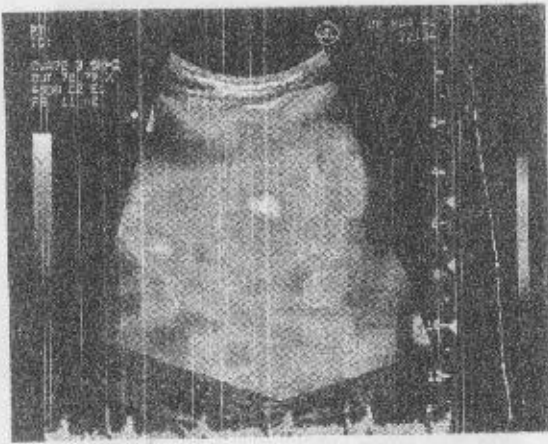


Fig 20.b CON before correction

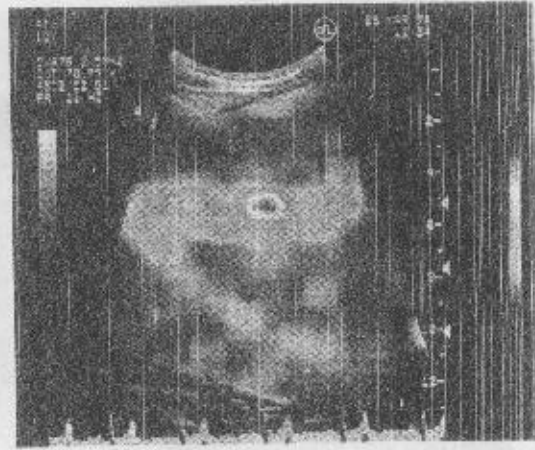


Fig 20.b CON after correction

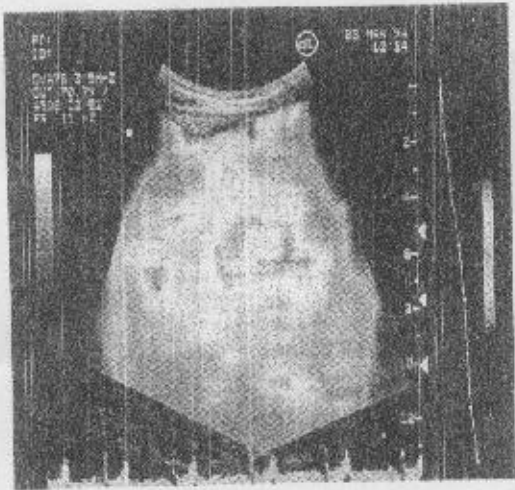


Fig 21.a TFDMC before correction

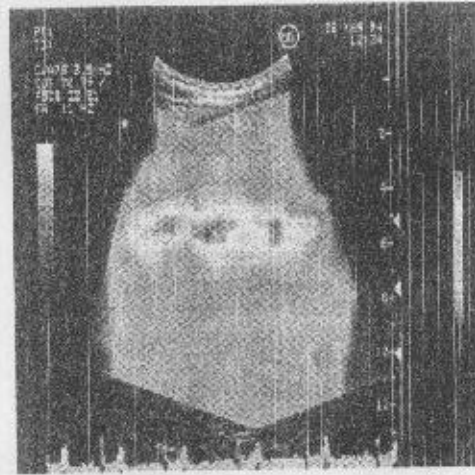


Fig 21.a TFDMC after correction



The next table shows in brief the changes for textural parameters after correction

Parameters increased after correction	Parameters decreased after correction
MGL	VAR
Absvar+	Absv+
PER90	BSC
PER10	TFDMC
COR Slightly increased at the center and decreased at the edges	
CON increased at the focal zone	
ATN	
ENT	

DISCUSSION AND CONCLUSION

In this paper we have presented the importance of mapping for texture parameters and the correction for machine dependencies on the overall the ultrasound images. It is clear that correction has a large impact for the images where the images show increasing in the brightness, contrast and homogeneity (improved visual inspection for sonographer). This analysis shows the effect of the corrections of ultrasound images for the machine dependencies and the impact change for all the textural parameters.

Our future work shall investigate every parameters at a time for different organ images (kidney, Spleen, Bladder) these corrections may improve the segmentation accuracy.

ACKNOWLEDGMENT

Prof.Dr. A.M.Youssef is acknowledged for his unlimited help to do this work also. Also, I would like to thank the Eng. Ayman Khalifa for his unlimited support for this work.

REFERENCES

- [1] Parker, K.J., Lerner, R.M., Waag R.C., Comparison of techniques for In-Vivo attenuation measurements IEEE Transactions on Biomedical Engineering, 35, 1064-1067, 1988.
- [2] Robert C. Waag, "A review of tissue characterization from ultrasonic scattering", IEEE Transaction on BME., vol. 31, NO. 12, DEC. 1984.
- [3] Verhoeven JTM. "Improvement of echographic image quality by data analysis and processing", Proefschrift K. Universiteit Nijmegen, 20 april 1994.
- [4] A. M. Badawi, A. M. Youssef, "Effect of Static Compression on the Acoustical and Textural Parameters of the Liver with Correlation to Diffuse Diseases," Annual Meeting of Egy. Society of Gastro. and Egy. Soc. of Ultras., December 1992.
- [5] A. M. Badawi, A. M. Youssef, "Tissue Characterization of Diffuse Liver Diseases Using Neural Nets," Annual Meeting of Egy. Soc. of Gastro. and Egy. Soc. of Ultrasonography, December 1992.
- [6] Y. M. Kadah, Aly A. Farag, Jacek M. Zurada, A. M. Badawi, Abou-Bakr M. Youssef, "Quantitative Algorithms for Tissue Characterization of Liver Disease from Ultrasound Images", IEEE Medical imaging journal, Vol 3, August, 1996
- [7] A.M Badawi, Ayman Khalifa, Abou-Bakr M. Youssef, " Quantitative tissue characterization program, computing and color-mapping of ultrasound parameters for

computerized diagnosis of liver pathologies" ICECS'97 Cairo, p.1053, December 1997.

[8] A.M. Badawi, - Quantitative Techniques and Algorithms for Ultrasound Tissue Characterization of Liver Diseases-, Ph.D. Faculty of Eng. Cairo Univ.1996.

[9] Roman Kuc, "Clinical Application of An Ultrasound Attenuation Coefficient Estimation Technique for Liver Pathology", IEEE Transaction on Biomedical Engineering, vol. BME-27, NO. 6, June 1980.

[10] P.He and J,F.Greenleaf, "Attenuation estimation on phantoms- A stability test, "Ultrason. Imaging, vol.8,pp.1-10,1986.

[11] F.A.Duck and C.R.Hill, "Acoustic attenuation reconstruction from backscattered ultrasound images, "in Computer Aided Tomography and Ultrasonics in Medicine, J.Raviv,J,F.Greenleaf, and G.T.Herman,Eds, Amsterdam:North-Holland,1979.

[12] E. Walach et. al , "Local tissue attenuation images based on pulsed echo ultrasound scan,"Trans. on BME, Vol. 36, No. 2, Feb. 1989.